

## Original Studies

# Pimecrolimus for the Treatment of Vulvar Lichen Sclerosus in a Premenarchal Girl

Andrew T. Goldstein, MD<sup>1</sup>, Stanley C. Marinoff, MD, MPH<sup>2</sup>, and Kurt Christopher, MD<sup>3</sup>

<sup>1</sup>Johns Hopkins School of Medicine, Baltimore, Maryland, USA; <sup>2</sup>The George Washington University School of Medicine, Washington, DC, USA; <sup>3</sup>Beth Israel Medical Center, New York, New York, USA

**Abstract.** *Background:* Lichen sclerosus is a chronic cutaneous disorder with a predilection for the vulva. Lichen sclerosus affects more than one in 900 girls. Superpotent corticosteroids like clobetasol propionate are the most effective treatment for vulvar lichen sclerosus. However, recurrence after stopping steroids is very high. As repeated courses of corticosteroids are frequently needed, there are concerns about potential side effects. Therefore, a treatment regimen that does not rely on corticosteroids may be beneficial. As lichen sclerosus is a T-lymphocyte mediated disorder, it has been suggested that pimecrolimus, a topical T-lymphocyte inhibitor, may be safe and effective for the treatment of lichen sclerosus in children.

*Case report:* A 10-year-old girl with lichen sclerosus was initially treated with clobetasol. Remission was achieved, but 3 months later she had a recurrence. Subsequent treatment with clobetasol led to a breakdown of her peri-anal skin with a superimposed infection. She was then treated with pimecrolimus and remission was achieved. She has had no recurrence of active lichen sclerosus and has less burning with pimecrolimus than with clobetasol.

*Conclusion:* Pimecrolimus may be an effective treatment of vulvar lichen sclerosus. Pimecrolimus has been shown to be very safe in the pediatric population for the treatment of mild to moderate eczema, without causing dermal atrophy, tachyphylaxis, striae, rebound flares, or hypothalamic-pituitary axis suppression. As the recurrence rate of active lichen sclerosus in prepubertal girls treated with topical corticosteroids is high, and the majority of prepubertal girls with lichen sclerosus continue to have disease after menarche, a treatment regimen that does not rely on corticosteroids may be beneficial.

---

**Key Words.** Children—Vulva—Lichen sclerosus—Tacrolimus/analogs & derivatives/therapeutic use

---

*Address correspondence to:* Andrew T. Goldstein, MD, 2002 Medical Parkway, Suite 215 Annapolis, MD 21401; E-mail: [obstetrics@yahoo.com](mailto:obstetrics@yahoo.com)

*Synopsis:* Pimecrolimus, a topical macrolide immunosuppressant, is an effective and safe treatment for childhood vulvar lichen sclerosus.

## Introduction

Lichen sclerosus is a T-lymphocyte mediated chronic cutaneous disorder with a predilection for the vulva. The prevalence of childhood lichen sclerosus has been estimated to be more than one in 900 girls.<sup>1,2</sup> The typical lesions of lichen sclerosus are white plaques, often with areas of ecchymosis, excoriation, and ulceration. Often, there is destruction of vulvar architecture with scarring of the clitoral prepuce, resorption of the labia minora, and narrowing of the introitus. Historically, treatments for lichen sclerosus have included topical estrogens, testosterone, progesterone, retinoids, and oral chloroquine.<sup>3–6</sup> In the early 1990s, several well-designed studies demonstrated that clobetasol propionate, a superpotent topical corticosteroid, is the most effective treatment for vulvar lichen sclerosus in adult women.<sup>3,4,7,8</sup> Subsequently, there have been three studies examining ultra potent corticosteroids for the treatment of lichen sclerosus in children.<sup>9–11</sup> These studies demonstrated the safety and efficacy of superpotent topical corticosteroids in children, but also showed a recurrence rate of up to 82% after stopping steroids.<sup>9</sup> In addition, side effects reported in these series include burning, irritation, erythema, and yeast superinfection.<sup>9–11</sup> As long-term usage, or repeated courses, of topical corticosteroids are frequently needed, there are concerns about potential side effects. Well-known side effects associated with long-term topical corticosteroid use include: thinning of the dermis, rebound reactions, striae formation, systemic absorption, hypothalamic-pituitary axis suppression, and fungal infections.<sup>12–14</sup> In addition, improper use of superpotent corticosteroids can significantly increase the risk of these side effects. Therefore, a treatment regimen that does not rely on corticosteroids may be beneficial for the treatment of childhood lichen sclerosus.

It has been suggested that pimecrolimus, a topical macrolide immunosuppressant, may be safe and efficacious for the treatment of vulvar lichen sclerosus in

children. Pimecrolimus inhibits T-cell activity by inhibiting calcineurin-dependent dephosphorylation-activation of specific nuclear factors, thus preventing transcription of pro-inflammatory cytokines including interleukin 2, 4, 10, and interferon gamma.<sup>15</sup> Pimecrolimus is FDA approved for the treatment of mild to moderate eczema in children 2 years old and greater.

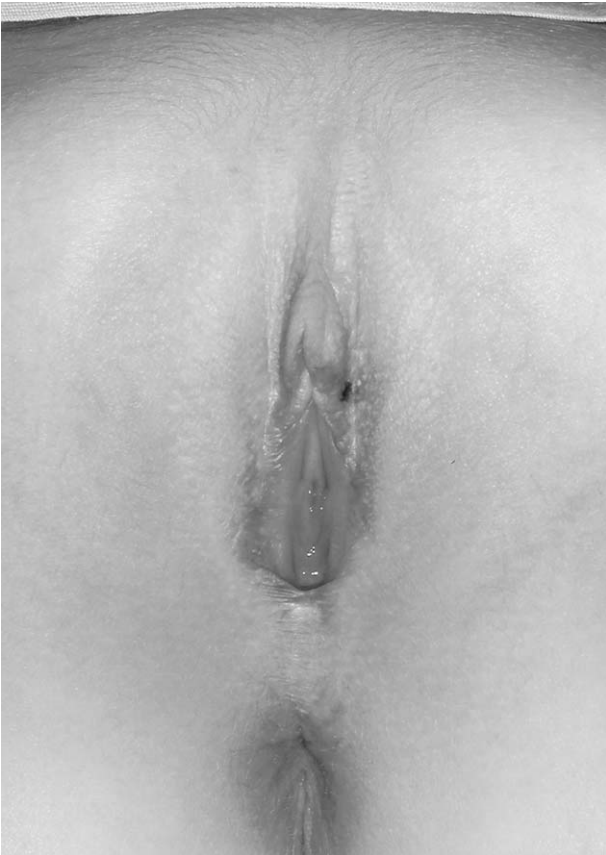### Case Report

A premenarchal 10-year-old girl with a 16-month history of biopsy proven vulvar lichen sclerosus was initially treated with clobetasol ointment 0.05% daily for 3 months. Remission of lichen sclerosus was achieved, but 5 months after cessation of the clobetasol she had a recurrence of active disease. Remission was again achieved with clobetasol, but during this second treatment course she developed breakdown of her perianal skin and had a severe mixed bacterial and yeast infection that was treated with cephalexin and fluconazole. Four months later, she developed a recurrence of active lichen sclerosus (Fig. 1). After a lengthy discussion with the patient and her parents, she was treated with 1% pimecrolimus cream (Elidel, Novartis Pharmaceuticals). She used the pimecrolimus

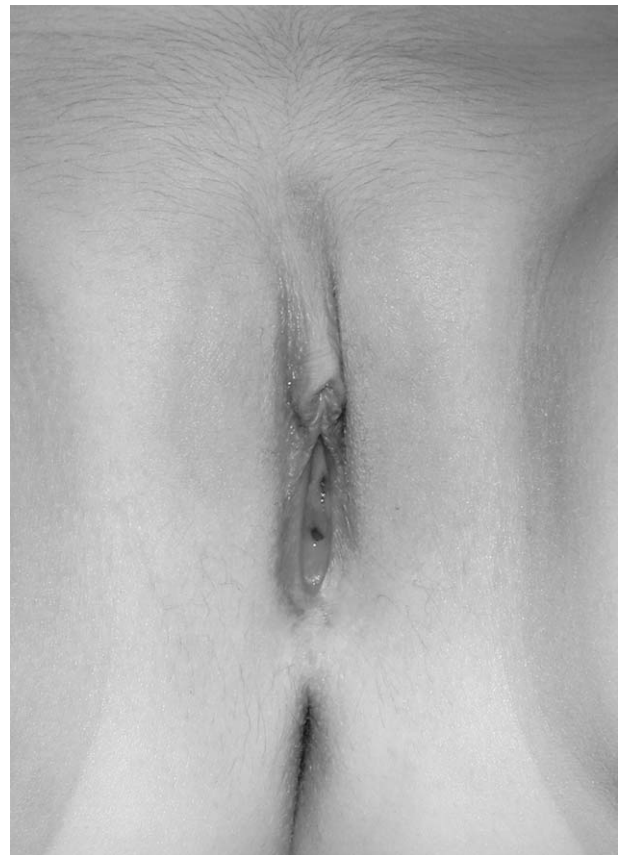
cream twice daily for 3 months and has continued using it every other day for the last 6 months. Remission was achieved within 6 weeks and she has had no recurrence of active lichen sclerosus (Fig. 2). She has had no complications and subjectively has less burning with the pimecrolimus as compared to the clobetasol.

### Discussion

In this case, pimecrolimus, a topical macrolide immunosuppressant, was safe and effective in the treatment of vulvar lichen sclerosus. Pimecrolimus has been shown to be very safe in the pediatric population without causing dermal atrophy, tachyphylaxis, striae, rebound flares, vasoconstriction, telangiectasia, or hypothalamic-pituitary axis suppression.<sup>16</sup> Pharmacokinetic studies have shown very low blood levels of pimecrolimus following topical application, with no accumulation after repeated applications.<sup>15</sup> As the recurrence rate of active lichen sclerosus in prepubertal girls treated with topical corticosteroids is high, and recent studies suggest that between 75% and 97% of prepubertal girls with lichen sclerosus continue to have



**Fig. 1.** Vulvar lichen sclerosus prior to treatment with pimecrolimus.



**Fig. 2.** Vulvar lichen sclerosus after a 6-week treatment with pimecrolimus.

disease after menarche,<sup>17,18</sup> a treatment regimen that does not rely on corticosteroids may be beneficial.

Lichen sclerosus is a T-lymphocyte mediated skin disorder. As pimecrolimus inhibits T-lymphocytes, it is plausible that pimecrolimus will prove to be a very effective and safe treatment for lichen sclerosus. Therefore, a randomized trial comparing pimecrolimus and clobetasol should be performed to determine which is the safest and most efficacious in the long-term treatment of lichen sclerosus.

## References

1. Lukowsky A, Muche JM, Sterry W, et al: Detection of expanded T cell clones in skin biopsy samples of patients with lichen sclerosus et atrophicus by T cell receptor-gamma polymerase chain reaction assays. *J Invest Dermatol* 2000; 115:254
2. Powell J, Wojnarowska F: Childhood vulvar lichen sclerosus: an increasingly common problem. *J Am Acad Dermatol* 2001; 44:803
3. Bornstein J, Heifetz S, Kellner Y, et al: Clobetasol dipropionate 0.05% versus testosterone propionate 2% topical application for severe vulvar lichen sclerosus. *Am J Obstet Gynecol* 1998; 178:80
4. Bracco GL, Carli P, Sonni L, et al: Clinical and histologic effects of topical treatments of vulvar lichen sclerosus. A critical evaluation. *J Reprod Med* 1993; 38:37
5. Wakelin SH, James MP: Extensive lichen sclerosus et atrophicus with bullae and ulceration—Improvement with hydroxychloroquine. *Clin Exp Dermatol* 1994; 19:332
6. Virgili A, Corazza M, Bianchi A, et al: Open study of topical 0.025% tretinoin in the treatment of vulvar lichen sclerosus. One year of therapy. *J Reprod Med* 1995; 40:614
7. Dalziel KL, Millard PR, Wojnarowska F: The treatment of vulval lichen sclerosus with a very potent topical steroid (clobetasol propionate 0.05%) cream. *Br J Dermatol* 1991; 124:461
8. Dalziel KL, Wojnarowska F: Long-term control of vulval lichen sclerosus after treatment with a potent topical steroid cream. *J Reprod Med* 1993; 38:25
9. Smith YR, Quint EH: Clobetasol propionate in the treatment of premenarchal vulvar lichen sclerosus. *Obstet Gynecol* 2001; 98:588
10. Fischer G, Rogers M: Treatment of childhood vulvar lichen sclerosus with potent topical corticosteroid. *Pediatr Dermatol* 1997; 14:235
11. Garzon MC, Paller AS: Ultrapotent topical corticosteroid treatment of childhood genital lichen sclerosus. *Arch Dermatol* 1999; 135:525
12. Cherian MP, AbdulJabbar M: Cushing's syndrome and adrenal suppression from percutaneous absorption of clobetasol propionate in infants. *Saudi Med J* 2001; 22:1139
13. Lubach D, Rath J, Kietzmann M: Steroid-induced dermal thinning: discontinuous application of clobetasol-17-propionate ointment. *Dermatology* 1992; 185:44
14. Pierard GE, Pierard-Franchimont C, Ben Mosbah T, et al: Adverse effects of topical corticosteroids. *Acta Derm Venereol Suppl (Stockh)* 1989; 151:26
15. Gupta A, Chow M: Pimecrolimus: A review. *J Eur Acad Dermatol Venereol* 2003; 17:493
16. Eichenfield LF, Beck L: Elidel (pimecrolimus) cream 1%: a nonsteroidal topical agent for the treatment of atopic dermatitis. *J Allergy Clin Immunol* 2003; 111:1153
17. Powell J, Wojnarowska F: Childhood vulvar lichen sclerosus. The course after puberty. *J Reprod Med* 2002; 47:706
18. Ridley CM: Genital lichen sclerosus (lichen sclerosus et atrophicus) in childhood and adolescence. *J R Soc Med* 1993; 86:69